


**PEDIATRIC UROLOGY CASE REPORTS**

ISSN 2148-2969

<http://www.pediatricurologycasereports.com>**Abdominal flap for penis augmentation in extrophy-epispadia complex: A case report****Luiz G. Freitas Filho<sup>1</sup>, Cassius M. Silva<sup>2</sup>, Karine F. Meyer<sup>3</sup>, Fernando S. Rios<sup>2</sup>, Felipe Toledo<sup>2</sup>, Luiz J. Budib<sup>2</sup>**<sup>1</sup>*Department of Pediatric Urology, Federal University of São Paulo and Hospital Santa Marcelina, Brazil*<sup>2</sup>*Department of Urology, Hospital Santa Marcelina, Brazil*<sup>3</sup>*Department of Pediatric Urology, Hospital Santa Marcelina, Brazil***ABSTRACT**

The extrophy-epispadias complex is a rare and difficult to treat condition, whose best management involves the participation of multidisciplinary teams. Because those patients' penis is short, with a broad basis and, usually, with dorsal chordee, there is an important demand to improve its esthetical appearance and to enlarge it. We present the case of a patient who underwent the construction of an abdominal wall flap that considerably improved the penile appearance and enlarged it by approximately 4 cm.

**Key Words:** Bladder extrophy; epispadias; cosmetic appearance; abdominal flap.

*Copyright © 2019 pediatricurologycasereports.com*

*Correspondence: Luiz G. Freitas Filho, M.D., Ph.D.  
Rua Batista Cepelos 87 – ap 6104109-120 São Paulo  
Brazil*

*E mail: [luizfreitasepm@gmail.com](mailto:luizfreitasepm@gmail.com)*

*ORCID ID: <https://orcid.org/0000-0003-2087-5878>*

*Received 2019-01-07, Revision 2019-01-28*

*Accepted 2019-01-31*

*Publication Date 2019-03-01*

**Introduction**

Children with the “extrophy-epispadias complex” (EEC) pose a great challenge to the multidisciplinary teams treating them. In general, those children undergo multiple surgical procedures that sometimes fail to solve major problems such as the acquisition of urinary continence and reconstruction of their external genital organs in such a manner as to make them suitable for sexual intercourse [1].

In a previous paper we showed that EEC patients' corporal image and emotional development may be severely affected by both genital deformity and the reconstructive surgery [2].

We present the case of a young man with EEC complex in whom a new abdominal skin flap was used to cover the penile body following full mobilization of the corpora cavernosa.

**Case report**

A 19 year old young man presenting with bladder extrophy, who at fifteen days of life underwent bladder plate closure, correction of the epispadia and posterior osteotomy of the iliac bones, using the Mitchell technique for urethral reconstruction [3]. At 6 years of age he underwent ileocystoplasty, confection of an

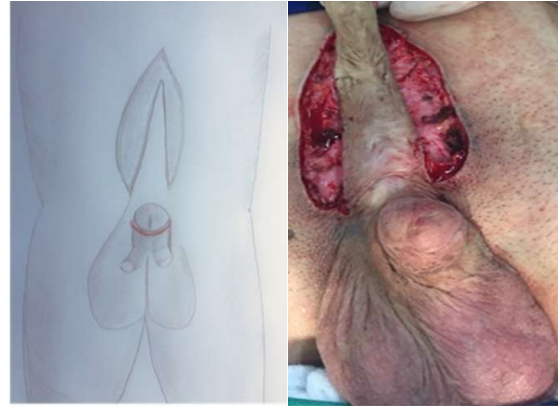appendicovesicostomy (Mitrofanoff procedure), bilateral ureteral reimplantation, Mitchell procedure on the bladder neck and construction of a “Sling” by using a rectus abdominis flap. Having failed to become continent, at age 15 he underwent closure of the bladder neck. Socially well adjusted, he constantly requested a surgical intervention for penile enlargement. In February 2017 he underwent the first stage of the penile plastic surgery, as described below.

**Technique**

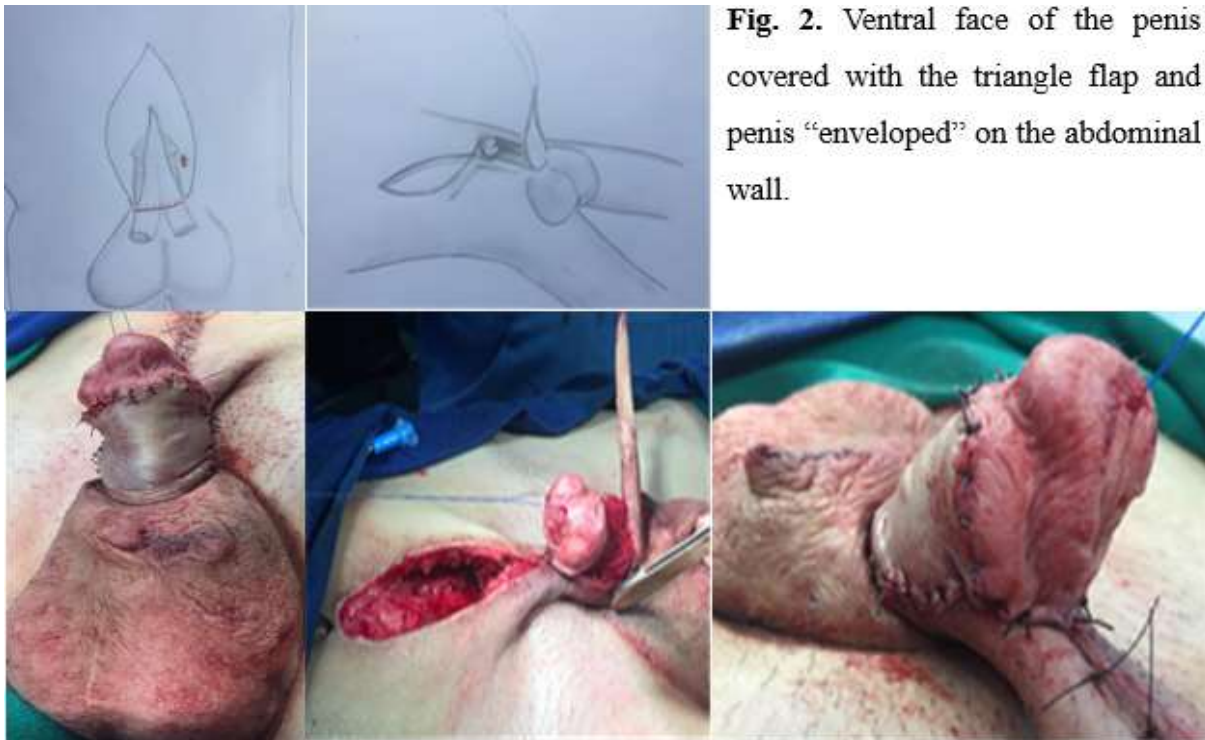
Full mobilization of both corporal bodies, and use of a long triangular skin flap whose base is located on the hypogastric portion of the abdomen. The penis was “degloved” of its skin by means of an incision in the transition between the penile mucosa and skin. The incision was closed and the penis with the mobilized corporal bodies was transferred to

the abdomen and covered with the triangular flap in its ventral face and involved in the abdominal skin in its dorsal face. Six months later the penis was separated from the abdomen (Fig. 1,2,3).

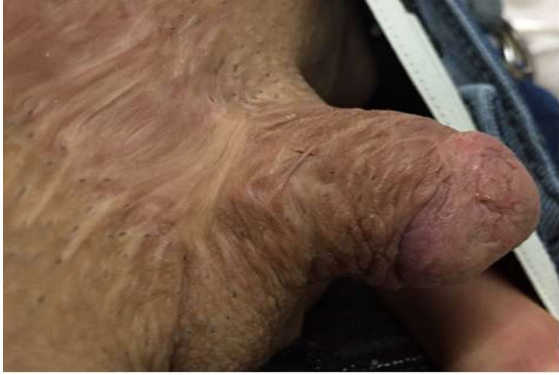Currently he is well, having gained more than 4 cm in penile body length (Fig. 3).



**Fig. 1.** Construction of a lower base triangle flap the abdominal wall.



**Fig. 2.** Ventral face of the penis covered with the triangle flap and penis “enveloped” on the abdominal wall.



**Fig. 3.** Penile aspect almost 1 year after the confection of an abdominal wall flap. Despite the skin scarring, the skin coverage allowed for accommodation of the corporal bodies.

### Discussion

EEC is a malformation that involves alterations in the lower abdominal wall, pelvic floor, bladder, urethra, external genital organs and hip [4]. Alterations in the innervation, collagen tissue and smooth muscles of the bladder wall have also been reported [5]. The standard treatment involves a staged approach, with a bilateral osteotomy of the iliac bones in the first 48 hours of life, if possible [1,5].

Those children present, at pubertal age, hypertrophic scars and boys almost always have a broad base penis, short in length due to shorter corporal bodies and, usually, rotated and with a relevant dorsal curvature [6]. If a longer size of the penis is to be obtained, the corporal bodies must be broadly and completely mobilized, which usually implies absence of an adequate skin cover, thus preventing the penis from again “sinking” into the pubic fat.

Different techniques have been proposed to cover the penile body all of which using either local or scrotal skin flaps or grafts [2,7,8,9]. They are used at the time of the first intervention and in our case the technique proposed by Mitchell [3] had been used. In many cases, however, the lack of skin support

may lead, in the long term, the corporal bodies to “drop” and again be “buried” within the pubic fat.

We proposed the use of a triangular abdominal flap that raises the previously mobilized corporal bodies and that serves to cover the ventral face of the penis. To cover the dorsal face of the penis we constructed an abdominal wall flap that “holds” the penis elevated and keeps it richly irrigated. Our patient had an abdominal skin scar in the central area, which did not prevent us from using it. Six months later the penis is separated from the abdomen, allowing for a gain that may come to 4 cm in length.

There is still much to learn about the best way to correct external genital organs of males with EEC and the construction of such abdominal wall flap may represent a small however important collaboration for the final esthetic outcome.

### Compliance with ethical statements

*Conflicts of Interest:* None.

*Financial disclosure:* None.

*Consent:* All photos were taken with parental consent.

### References

- [1] Gearhart JP, Mathews R. Exstrophy-epispadias complex. In: Wein AJ, Kavoussi LR, Partin AW, Peters CA eds, *Campbell's Urology*, 11<sup>th</sup> ed, Vol IV, CHpt 139. Elsevier, 2016, 3182-233.
- [2] Meyer KF, Freitas Filho LG, Martins DMS, Vaccari M, Carnevale J. The exstrophy-epispadias complex: is aesthetic appearance important? *BJU Int.* 2004; 93(7):1062-68.
- [3] Mitchell ME, Bägli DJ. Complete penile disassembly for epispadia repair: the Mitchell technique. *J Urol.* 1996; 155(1):300-4.

- [4]Stec AA, Pannu HK, Tadros YE, Spnsoller PD, Fishman EK, Gearhart JP. Pelvic floor anatomy in classic bladder exstrophy using 3-dimensional computerized tomography: initial insights. *J Urol.* 2001; 166(4):1444-49.
- [5]Poli-Marol ML, Watson JA, Gearhart JP. New basic science concepts in the treatment of classic bladder exstrophy. *Urology.* 2002; 60(5):749-55.
- [6]Woodhouse CRJ. Sexual function in boys born with exstrophy, myelomeningocele, and micropenis. *Urology.* 1998; 52(1):3-11.
- [7]Djorjevic M, Kojovic V, Bizic M, Majstorovic M, Vukadinovic V, Korac G, et al. Epispadia repair after failed surgery in childhood. *Eur J Pediatr Surg.* 2013; 23(1):67-71.
- [8]Pippi Salle JL, Jednak JP, Capolicchio JP, França IMP, Labie A, Gosalbez R. A ventral rotational skin flap to improve cosmesis and avoid chordee recurrence in epispadia repair. *BJU International.* 2002; 90(9):918-23.
- [9]Khoury AE, Papanikolau F, Afshar K, Zuker R. A novel approach to skin coverage for epispadia repair. *J Urol.* 2005; 173(4):1332-33.

