



## Case Report: Vaginostomy until further reconstruction for the management of hydrocolpos causing hydronephrosis

Paarth Kapadia<sup>1</sup>, Shreeya Popat<sup>2</sup>, Angela G. Mittal<sup>2,3</sup> 

<sup>1</sup>Baylor College of Medicine, Houston, TX, USA

<sup>2</sup>Scott Department of Urology, Baylor College of Medicine, Houston, TX, USA

<sup>3</sup>Department of Surgery, Texas Children's Hospital, Houston, TX, USA

### ABSTRACT

Hydrocolpos is a rare congenital genitourinary anomaly that can cause clinically significant urinary tract obstruction with oligohydramnios and hydronephrosis antenatally and renal failure postnatally. Here, we discuss the management of a neonate with hydrocolpos and renal failure. Vaginostomy tube and bladder catheterization have been described previously. However, in this population, external tubes can be difficult to manage and have a high propensity of failure. Therefore, the patient was managed via creation of a vaginostomy, which allowed for continuous passive drainage of fluid into a diaper and maintained a decompressed urinary tract until further reconstruction could be pursued.

**Key Words:** Neonatal hydronephrosis, vaginostomy, hydrocolpos, hydrometrocolpos, cloacal abnormality.

© 2020 [pediatricurologycasereports.com](http://www.pediatricurologycasereports.com)

 Dr. Angela G. Mittal

6701 Fannin St. Houston, TX 77030, USA

E-mail: [agmittal82@gmail.com](mailto:agmittal82@gmail.com)

Received: 2020-03-14 / Revisions: 2020-04-09

Accepted: 2020-06-25

Publication Date: 2020-09-01

### Introduction

Hydrocolpos is a rare congenital genitourinary anomaly marked by the presence of a distended vagina filled with fluid. Hydrometrocolpos is a related anomaly in which both the vagina and uterus are distended and filled with fluid. Hydrocolpos often develops secondarily to a spectrum of urogenital anomalies – including but not limited to transverse vaginal septum, urogenital sinus, vaginal atresia, and

imperforate hymen – that obstruct vaginal outflow and sometimes involve additional connections to the urinary tract and, thus, lead to fluid accumulation in the vagina [1]. In cases involving connections to the urinary tract, such as urogenital sinus, the fluid that builds up may be urine; these cases often present earlier, perinatally. In cases without connection to the urinary tract, such as imperforate hymen and distal vaginal atresia, the fluid is usually blood and menstrual contents; these cases may present later, peri-pubertally.

In many cases, the fluid accumulation can lead to clinically significant urinary tract obstruction. The detection and diagnosis of prenatal and neonatal hydrocolpos has been

described across multiple publications [2-5]. Antenatally, hydrocolpos can cause oligohydramnios and bilateral hydronephrosis, which can be detected on prenatal ultrasound. A lower abdominal mass, i.e. the distended vagina/uterus, may also be seen on imaging. Postnatally, hydrocolpos, that is severe enough to obstruct the urinary tract, can lead to acute renal failure. On neonatal physical exam, vaginal atresia or imperforate hymen and the aforementioned lower abdominal mass can be observed. Unfortunately, there is a paucity of literature discussing the management of hydrocolpos.

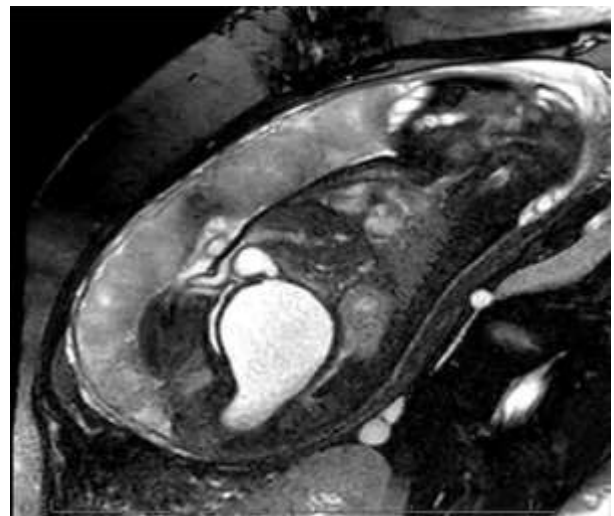
Previously described management options involve external tubes and/or catheters, i.e. a vaginostomy tube or bladder catheterization with either continuous or intermittent catheters [6–12]. These techniques provide a means of draining the abdominal fluid collection, thereby addressing the mass effect and resulting obstructive renal dysfunction. We present the surgical management of prenatal hydrocolpos via vaginostomy as a safe, reliable, and durable alternative to external tubes in pediatric patients.

### Case report

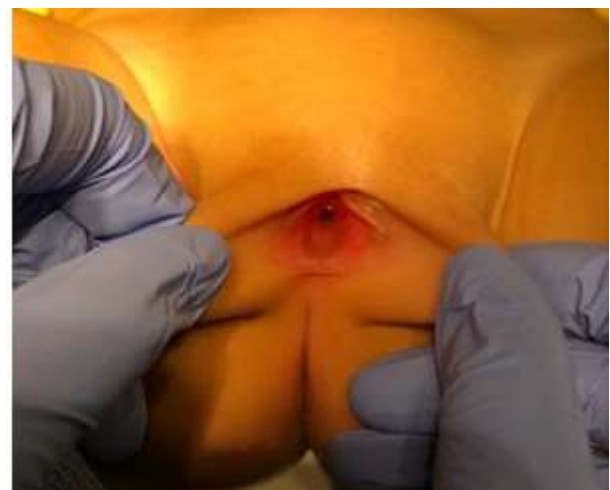A 24-year-old G1P0 female presented at 32 weeks gestation with a prenatal ultrasound revealing oligohydramnios and bilateral hydronephrosis in a female fetus. A large fluid collection posterior to the fetal bladder was also noted. Prenatal magnetic resonance imaging (MRI) identified it as a distended vagina (Fig.1).

Labor was induced at 36 weeks for oligohydramnios. Secondary to failure to progress, the baby was delivered via caesarean section. At birth, the patient had APGAR scores of 8 due to weak breathing and skin pallor, which improved after transient

continuous positive airway pressure (CPAP). She was taken to the neonatal intensive care unit (NICU) for further evaluation and monitoring. Physical exam revealed a distended abdomen with a palpable suprapubic mass extending 3 cm above the umbilicus. Genitourinary exam revealed two perineal openings: an anus and a single anterior opening (this is evident in Fig. 2).



**Fig. 1.** Prenatal MRI at 32 weeks estimated gestational age.



**Fig. 2.** Genitourinary examination at 2 years of age.

Abdominal ultrasound on day 1 of life revealed a markedly distended vagina (8 x 6.3 x 7 cm), decompressed bladder, and bilateral

hydronephrosis. Diagnostic work-up for disorders of sexual differentiation, including physical exam as above, serum electrolytes and labs, and abdominopelvic ultrasound, were performed without concern.

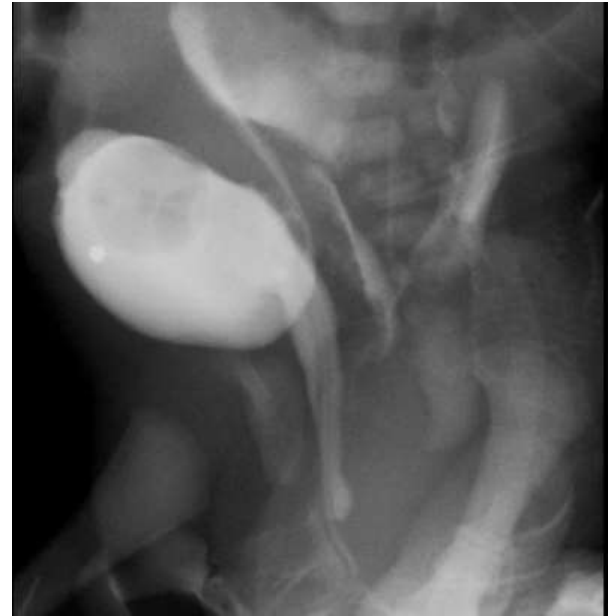On day 2 of life, the patient was taken for diagnostic cystoscopy/vaginoscopy and possible diversion. Cystoscopy revealed a distorted urethra angled anteriorly and a large mass abutting the bladder posteriorly; no vaginal opening or fistulous connection was seen.

The abdomen was then explored at the level of the mass. Intra-operative ultrasound located the distended vagina. Serous fluid was aspirated and found to have a fluid creatinine of 12.54 (serum creatinine 0.20), consistent with urine. The vagina was opened, and the wall was secured to the fascia and matured to the skin to create a vaginostomy. Vaginoscopy via the vaginostomy revealed a capacious vagina without a perineal opening.

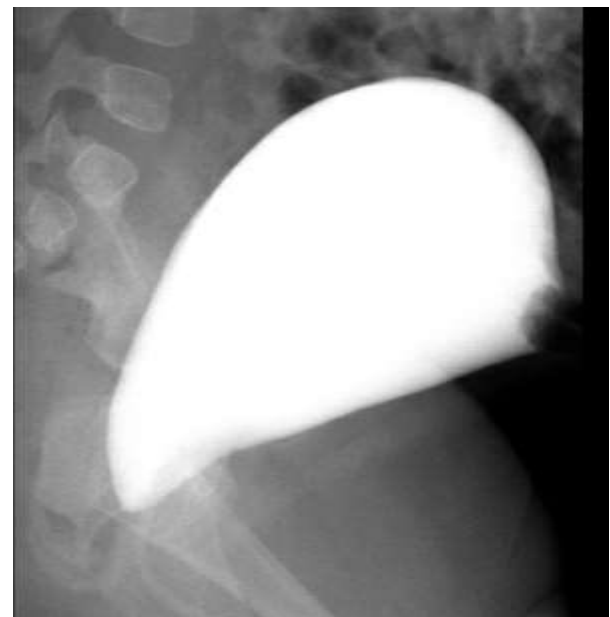
The patient was followed with serial renal ultrasounds, revealing a marked improvement in the hydronephrosis at 3 months of age, which remained stable for a follow-up of 15 months. Voiding cystourethrogram at 3 months of age revealed filling of the vagina with a questionable connection to the posterior urethra (Fig. 3). (Later examination also revealed bilateral ureteral orifices in normal orthotopic position). However, subsequent contrast radiograph at 9 months of age showed blind-ending vaginal cavity with no obvious connection to the bladder (Fig. 4).

At two years of age, the patient underwent anesthetized examination. This examination revealed the single anterior opening to be a space thought to be a common urogenital sinus. While there were mucosal folds along the distal aspect of this tract, no obvious openings to the vagina could be seen or

cannulated. We will await further maturation of the patient and discussions with family for shared decision-making prior to pursuing definitive reconstruction.



**Fig. 3.** Voiding cystourethrogram at 3 months.



**Fig. 4.** Radiograph at 9 months of age.

### **Discussion**

Hydrocolpos presents in 1/16,000–30,000 live births [13]. It is present more frequently in stillbirths due to its high level of concordance with lethal congenital anomalies [13]. In live

births presenting with hydrocolpos or hydrometrocolpos, the condition can have both local effects and systemic sequelae. Local effects are driven by the mass effect in the abdomen causing compression of surrounding structures, which could result in potential discomfort, functional constipation, perforation of the vagina, and (if the patient presents during puberty) cyclical pain during menstruation. These local effects could also be followed by systemic sequelae, such as life-threatening renal compromise (as in our case) and respiratory distress [7,14,15]. Therefore, prompt, effective, and durable treatment of this condition is paramount.

Prior literature has described management of clinically significant urinary tract obstruction secondary to hydrocolpos with vaginostomy tube or bladder catheterization [6–12]. While these methods are effective in the short-term, they pose significant risk of failure in the long-term [6,8,10,12]. Tubes and catheters can easily become clogged or dislodged in neonates. In addition, they can be bothersome for the patient and difficult to manage for the caregiver. As definitive surgical resolution of congenital anomalies is often complex and requires delay until after the neonatal period, a durable temporizing solution is necessary. Therefore, in this case, we performed a vaginostomy to allow continuous passive drainage of fluid into a diaper and maintain a decompressed urinary tract. Such diversion facilitates management with a diaper and without external tubes, until definitive reconstruction can be safely pursued. We propose that this management strategy may serve as a more stable, manageable, and comfortable solution for neonates born with hydrocolpos, yielding equivalent therapeutic results to vaginostomy tubes and catheterization.

### **Conclusion**

In patients with congenital genitourinary anomalies, hydrocolpos can cause clinically significant urinary tract obstruction. Management with vaginostomy tube or bladder drainage via continuous or intermittent catheterization has been described previously [14]. However, external tubes can easily get clogged or dislodged, especially in the pediatric population. Therefore, we propose vaginostomy as a safe and reliable alternative to decompress the urinary tract in children who will require prolonged diversion and/or delayed definitive reconstruction.

### **Compliance with ethical statements**

*Conflicts of Interest:* None.

*Financial disclosure:* None.

*Consent:* Informed and written consent were taken from patient and her parents to publish this case report.

### **ORCID iD of the author (s)**

*Paarth Kapadia / 0000-0003-3033-3351*

*Shreeya Popat / 0000-0002-3862-2767*

*Angela G. Mittal / 0000-0003-3160-9348*

### **References**

- [1] Cerrah Celayir A, Kurt G, Sahin C, et al. Spectrum of etiologies causing hydrometrocolpos. *J Neonatal Surg.* 2013;2(1):5.
- [2] Alici Davutoglu E, Yuksel MA, Yurtkal A, et al. Prenatal diagnosis of isolated foetal hydrocolpos secondary to congenital imperforate hymen mimicking ambiguous genitalia. *J Obstet Gynaecol J Inst Obstet Gynaecol.* 2017;37(2):248-49.
- [3] Capito C, Belarbi N, Paye Jaouen A, et al. Prenatal pelvic MRI: additional clues for assessment of urogenital obstructive

- anomalies. *J Pediatr Urol.* 2014;10(1):162-66.
- [4] Mallmann MR, Reutter H, Mack-Detlefsen B, et al. Prenatal Diagnosis of Hydro(metro)colpos: A Series of 20 Cases. *Fetal Diagn Ther.* 2019;45(1):62-68.
- [5] Tilahun B, Woldegebriel F, Wolde Z, et al. Hydrometrocolpos Presenting as a Huge Abdominal Swelling and Obstructive Uropathy in a 4 Day Old Newborn: A Diagnostic Challenge. *Ethiop J Health Sci.* 2016;26(1):89-91.
- [6] Chalmers DJ, Rove KO, Wiedel CA, et al. Clean intermittent catheterization as an initial management strategy provides for adequate preservation of renal function in newborns with persistent cloaca. *J Pediatr Urol.* 2015;11(4):211.e1-4.
- [7] Gupta I, Barson AJ. Hydrocolpos with peritonitis in the newborn. *J Clin Pathol.* 1980;33(7):679-83.
- [8] Mansouri R, Sander JC, Janzen NK, et al. A Case of Obstructed Hemivagina with Ectopic Ureter Leading to Severe Hydrocolpos and Contralateral Renal Outflow Tract Obstruction in a Neonate. *J Pediatr Adolesc Gynecol.* 2015;28(5):e131-33.
- [9] Murthy V, Costalez J, Weiner J, et al. Two neonates with congenital hydrocolpos. *Case Rep Pediatr.* 2013;2013:692504.
- [10] Reggiani G, Pizzol D, Trevisanuto D, et al. Successful management of giant hydrocolpos in a limited-resource setting. *Oxf Med Case Rep.* 2018;2018(7):omy031.
- [11] Speck KE, Arnold MA, Ivancic V, et al. Cloaca and hydrocolpos: laparoscopic-, cystoscopic- and colposcopic-assisted vaginostomy tube placement. *J Pediatr Surg.* 2014;49(12):1867-69.
- [12] Višnjić S, Bastić M, Marčec M, et al. Short-term “double natural orifice catheterization”: Nonoperative management of hydrocolpos in persistent cloaca patients - case series. *J Pediatr Surg.* 2018;53(4):718-21.
- [13] Khanna K, Sharma S, Gupta DK. Hydrometrocolpos etiology and management: past beckons the present. *Pediatr Surg Int.* 2018;34(3):249-61.