



Reflections on COVID-19 nasopharyngeal, fecal and peritoneal swabs in an infant with Wilms tumor: A case report

Alberto Mantovani,^{ID} Giulia Bortot, Elisa Negri, Chiara Cini, Maria Chiara Cianci, Luca Landi, Lorenzo Masieri

Department of Pediatric Urology, Meyer Children's Hospital, Viale Pieraccini 24, Florence, Italy

ABSTRACT

Proximal Sars-Cov-2 pandemic had radically changed the way surgeons work in many departments, forcing to reserve surgical treatment only for emergency and oncologic cases. We report a case of a ten months-old girl with right-sided Wilms tumor and a previous diagnosis of Sars-Cov-2 infection, who underwent open right nephrectomy. Surgery was planned after negativization of five nasopharyngeal tests, despite the simultaneous positivity of two rectal swabs. The procedure was performed safely with appropriate personal protective equipment (PPE). To better investigate viral excretion, the anesthetist repeated nasopharyngeal swab under general anesthesia, which resulted positive. At the same time, two peritoneal swabs were collected and showed the absence of the virus in the peritoneal fluid. This case highlights the importance of combining swabs from various sources to increase sensibility of the test. The value of nasopharyngeal swab under general anesthesia should be reinforced as it can result positive even after many negative tests. Very little is known about transmission of the virus through the peritoneum as both presence and absence of Sars-Cov-2 have been reported in the peritoneal fluid. Upcoming literature will clarify which particular conditions determine viral penetration in this anatomical district.

Key Words: COVID-19, peritoneal swab, Wilms tumor, nephrectomy, pediatric surgery, pediatric urology.

© 2020 [pediatricurologycasereports.com](http://www.pediatricurologycasereports.com)

✉ *Dr. Alberto Mantovani, FEAPU,
Department of Pediatric Urology, Meyer Children's
Hospital, Viale Pieraccini 24, Florence, Italy.*

E-mail: alberto.mantovani@meyer.it

Received: 2020-05-27 / Accepted: 2020-06-08

Publication Date: 2020-07-01

Introduction

During COVID-19 pandemic, pediatric surgery departments of most countries experienced a dramatic reduction in the

elective surgical activity, continuing to offer surgical treatment only for emergency and oncological cases [1-4]. Any patient currently approaching to surgery needs the diagnosis of COVID-19 positive or negative. The test has to be as quick and reliable as possible in order to take appropriate personal protective equipment (PPE) and pathway [5].

We present a case of Wilms tumor with different combination of nasopharyngeal, fecal

and peritoneal swabs results during the hospitalization and give a prospective thought for the management of surgical patients during the easing of the lockdowns and beyond.

Case report

A ten months-old girl was admitted the 1st of March 2020 to the emergency department with hyperpyrexia, signs of urinary tract infection (UTI) and a palpable right abdominal mass. US scan confirmed the presence of a right renal mass of 10 cm and urine culture showed *E. coli* infection. Intravenous antibiotic therapy was initiated. Magnetic resonance imaging (MRI) (Fig. 1A, B) and computed tomography (CT) scans confirmed the suspect of right localized Wilms tumor and she was commenced on chemotherapy following the Umbrella SIOP-RTSG 2016 Wilms tumor protocol [1]. The first two cycles were uneventful.

Two days after the third cycle of chemotherapy she came to the local emergency department with hyperpyrexia: urinary stick and routine blood tests were negative but nasopharyngeal swab for Sars-Cov-2 turned positive. Chest-CT was subsequently performed and was negative. She was then admitted through a Covid-19 positive patient pathway and isolated. The fourth cycle of chemotherapy was postponed. During the hospitalization she became afebrile, with no pulmonary involvement. She was discharged four days later with two negative nasopharyngeal swabs. Two weeks later hyperpyrexia reoccurred without any other sign or symptoms. Nasopharyngeal swabs were repeated on the patient and patient's mum: they resulted negative and positive respectively. Urine culture showed multi-drug resistant *Klebsiella Pneumoniae*. Chest X-ray was negative. Subsequently the baby was hospitalized again following COVID-19

positive patient pathway. UTI was treated with Meropenem according to antibiogram.

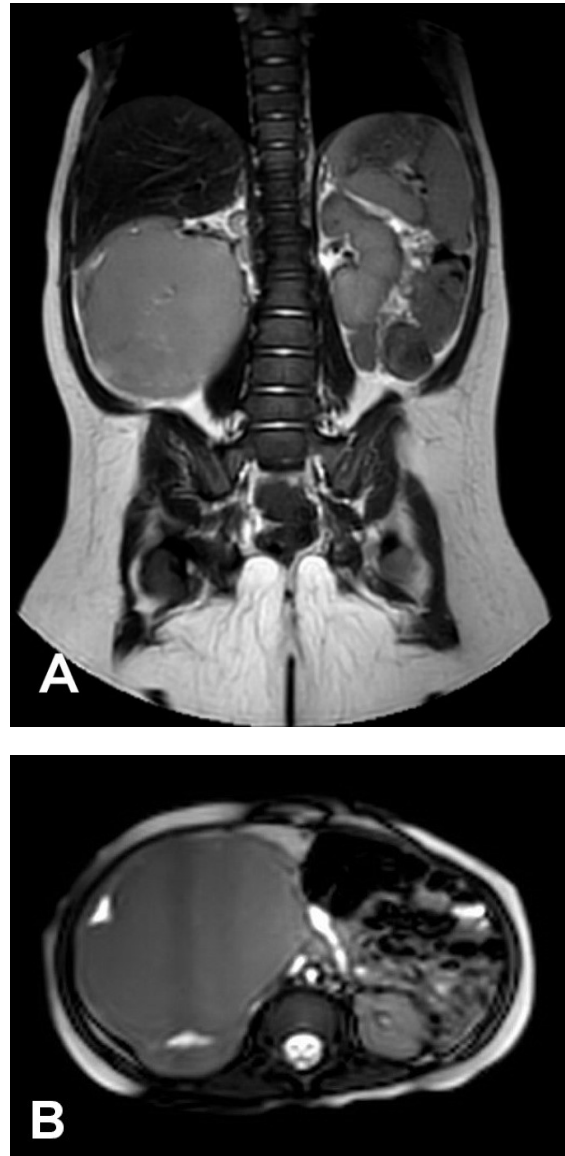


Fig. 1A, B. Right Wilms tumor at pre-op MRI after 4 cycles of chemotherapy.

During the hospitalization nasopharyngeal swabs for Sars-Cov-2 were performed every 48h for 12 days, and they always resulted negative. The virus was then searched on feces: real time polymerase chain reaction (PCR) performed on rectal swabs resulted positive in two different specimens, despite the negativity of simultaneous nasopharyngeal

samples. Patient's clinical conditions progressively improved and she received the 4th cycle of chemotherapy. Checked-MRI showed no significant improvement of mass volume. In agreement with anesthesiologists, considering multiple negative pharyngeal swabs and adequate time from last chemotherapy, open radical right nephrectomy was considered safe and was performed.

To investigate the pattern of viral excretion the anesthetist repeated nasopharyngeal swab under general anesthesia (GA), which resulted positive for Sars-Cov-2.

Moreover, two swabs of peritoneal fluid taken by the surgeon showed no virus. No intra-operative complications were recorded and the recovery was uneventful.

Discussion

Knowledge about COVID-19 is rapidly emerging through scientific publications in different fields of medicine. Recent guidelines focused on the revision of the indication for surgery with the aim to minimize theatre utilization for non-urgent conditions [2]. Parallel to that, particular attention has been paid on the safety of those procedures proposed during pandemic. First of all, all patients undergoing surgery should be tested for COVID-19. The results will influence the patient's pathways and staff behaviors within the hospital, including theatre [3]. The test currently used worldwide is the nasopharyngeal swab: viral nucleic acid (NAT: nucleic acid test) is searched using real-time reverse transcriptase-polymerase chain reaction (RT-PCR). This can confirm the virus infection within 2 hours [4]. It is also known that nasopharyngeal swabs are more sensitive when symptoms first emerge and swabs from both sides are often combined to increase sensitivity [6]. Previous authors suggested a

sensitivity as low as 32 to 63% in children [7]. Reasons for the low efficiency may include immature development of nucleic acid detection technology, variation in detection rate from different manufacturers, low patient viral load or improper clinical sampling [8]. The case presented shows how the nasopharyngeal test can be misleading, even in the unusual scenario of multiple negative results. In fact, only the swab taken under GA was positive for Sars-Cov-2 in our case. As a consequence, the power of the test must depend in part on the experience of who performs it, being this rule new for many healthcare workers who often learned the procedure without appropriate training. Moreover, an impact on the final results must be also given by the patient compliance during the swab, which is minimal in case of young children. For those reasons we strongly recommend to perform always another nasopharyngeal swab under GA at the beginning of the procedure, which can change the pathway of the patient in case of an unrecognized positivity at the time of admission. Fortunately, our case had positive rectal swab, which determined a safe COVID-19 pathway. Rectal swabs have already shown to persist positive even after the negativization of nasopharyngeal test, as reported by Xu *et al* [9]. Moreover, the same author described two patients discharged after two consecutive negative rectal swabs, who turned positive at the same test 7 and 13 days after discharge, according with the theory of different phases of viral excretion [9]. Those findings suggest that rectal swab-testing may be more useful than nasopharyngeal ones in judging the state of the infection and determining the timing for termination of quarantine. Xiao *et al* recently gave evidence of replication-competent virus in feces, confirming the potential for fecal-oral

transmission [10]. Doing many swabs in different locations and at different times during the patient hospitalization may lead to confusion and unnecessary delay in procedures, as well as risks for safety of medical staff or, on the other hand, inappropriate use of PPE. Development of an accurate quick-test for Sars-Cov-2 is essential and many laboratories are working on this topic [11]. Even if Sars-Cov-2 has been found in many specimens from different anatomical sites, data are currently lacking regarding the incidence of Sars-Cov-2 in the abdominal cavity, in patients with positive nasopharyngeal or rectal swab [6]. This has led to suggest open approach instead of laparoscopy, or the insufflation or the disinflation of the abdomen in a closed circuit, in those cases where laparoscopy was indicated and before converting from laparoscopy to open surgery [12]. In our case, no viral nucleic acid, tested using RT-PCR, was found on two different peritoneal swabs taken at the time of surgery, while pharyngeal swab taken at the same time resulted positive. However, Coccolini *et al* have recently identified virus from peritoneal swab in a 78 years old man with Sars-Cov-2 bilateral pneumonia, who underwent surgery for intestinal mechanical obstruction due to small bowel volvulus [13]. We recommend taking peritoneal swabs during any abdominal surgery in order to avoid missing positive patients who might contribute to spread the infection if not recognized and adequately isolated.

Conclusions

COVID19 will probably influence our practice for the next year at least. It is important to test the patients appropriately and possibly from more than one source. This will help to understand viral behavior among different

cohorts of subjects and act consequently. Our case report shows the possible value of nasopharyngeal test under GA independently from the result of previous swabs. Moreover, the combination of swabs from various sources should improve the sensibility to identify patients who are carrying the virus.

Hopefully, more data from peritoneal swabs will be soon available for adult and children, helping the decision-making process before undertaking surgery.

Compliance with ethical statements

Conflicts of Interest: None.

Financial disclosure: None.

Consent: Informed and written consent were taken from patient and her parents to publish this case report.

ORCID iD of the author (s)

Alberto Mantovani / 0000-0001-6877-9848

Giulia Bortot / 0000-0002-9874-3675

Elisa Negri / 0000-0002-1628-7048

Chiara Cini / 0000-0003-4644-972X

Maria Chiara Cianci / 0000-0003-1907-0431

Luca Landi / 0000-0002-6513-2472

Lorenzo Masieri / 0000-0002-2020-3150

References

- [1] Vujančić GM, Gessler M, Ooms AHAG, et al. The UMBRELLA SIOP-RTSG 2016 Wilms tumour pathology and molecular biology protocol. *Nat Rev Urol.* 2018; 15(11): 693-701.
- [2] Quaedackers JSLT, Stein R, Bhatt N, et al. Clinical and surgical consequences of the COVID-19 pandemic for patients with pediatric urological problems: Statement of the EAU guidelines panel for paediatric urology, March 30 2020 [published online ahead of print, 2020 Apr 9]. *J Pediatr Urol.* 2020;16(3):284-87.

- [3] Cini C, Bortot G, Sforza S, et al. Paediatric urology practice during COVID-19 pandemic [published online ahead of print, 2020 Apr 25]. *J Pediatr Urol.* 2020;16(3):295-96.
- [4] Liu W, Zhang Q, Chen J, et al. Detection of Covid-19 in children in early January 2020 in Wuhan, China. *N Engl J Med.* 2020; 382(14):1370-72.
- [5] Bilgin S, Kurtkulagi O, Kahveci GB et al. Millennium pandemic: A review of coronavirus disease (COVID-19). *Exp Biomed Res.* 2020; 3(2): 117-25.
- [6] Beeching NJ, Fletcher TE, Beadsworth MBJ. Covid-19: testing times. *BMJ.* 2020; 369:m1403.
- [7] Wang W, Xu Y, Gao R, et al. Detection of SARS-CoV-2 in Different Types of Clinical Specimens [published online ahead of print, 2020 Mar 11]. *JAMA.* 2020; 323(18):1843-44.
- [8] Fang Y, Zhang H, Xie J, et al. Sensitivity of Chest CT for COVID-19: Comparison to RT-PCR [published online ahead of print, 2020 Feb 19]. *Radiology.* 2020; 200432.
- [9] Xu Y, Li X, Zhu B, et al. Characteristics of pediatric SARS-CoV-2 infection and potential evidence for persistent fecal viral shedding. *Nat Med.* 2020; 26(4):502-505.
- [10] Xiao F, Tang M, Zheng X, et al. Evidence for Gastrointestinal Infection of SARS-CoV-2. *Gastroenterology.* 2020; 158(6):1831-1833.e3.
- [11] Esbin MN, Whitney ON, Chong S, et al. Overcoming the bottleneck to widespread testing: a rapid review of nucleic acid testing approaches for COVID-19 detection. *RNA.* 2020;26(7):771-83.
- [12] Zheng MH, Boni L, Fingerhut A. Minimally Invasive Surgery and the Novel Coronavirus Outbreak: Lessons Learned in China and Italy [published online ahead of print, 2020 Mar 26]. *Ann Surg.* 2020;10.1097/SLA.0000000000003924.
- [13] Coccolini F, Tartaglia D, Puglisi A et al. SARS-CoV-2 is present in peritoneal fluid in COVID-19 patients. *Ann Surg.* 2020. [Epub ahead of print].